

CASE REPORT

A child with a deletion in the monocarboxylate transporter 8 gene: 7-year follow-up and effects of thyroid hormone treatment

Amnon Zung, Theo J Visser¹, André G Uitterlinden¹, Fernando Rivadeneira¹ and Edith C H Friesema¹*Pediatric Endocrinology Unit, Kaplan Medical Center, Affiliated with the Hebrew University of Jerusalem, Rehovot 76100, Israel and ¹Department of Internal Medicine, Erasmus MC, Rotterdam, The Netherlands**(Correspondence should be addressed to A Zung; Email: amzung2@bezeqint.net)*

Abstract

Objective: The monocarboxylate transporter 8 (MCT8; *SLC16A2*) has a pivotal role in neuronal triiodothyronine (T₃) uptake. Mutations of this transporter determine a distinct X-linked psychomotor retardation syndrome (Allan–Herndon–Dudley syndrome (AHDS)) that is attributed to disturbed thyroid hormone levels, especially elevated T₃ levels. We describe the genetic analysis of the *MCT8* gene in a patient suspected for AHDS and the clinical and endocrine effects of L-thyroxine (LT₄) or liothyronine (LT₃) treatment intending to overcome the T₃ uptake resistance through alternative transporters.

Methods: The six exons of the *MCT8* gene were amplified individually by PCR. As multiple exons were missing, the length of the X-chromosomal deletion was determined by a dense SNP array, followed by PCR-based fine mapping to define the exact borders of the deleted segment. The clinical and endocrine data of the patient during 6.5 years of LT₄ treatment and two periods (3 months each) of low- and high-dose LT₃ were evaluated.

Results: A partial deletion of the *MCT8* gene (comprising five of six exons) was detected, confirming the suspected AHDS. MCT8 dysfunction was associated with partial resistance to T₃ at the hypothalamus and pituitary level, with normal responsiveness at the peripheral organs (liver and cardiovascular system). Thyroid hormone administration had no beneficial effect on the neurological status of the patient.

Conclusion: We identified a 70 kb deletion encompassing exons 2–6 of the *MCT8* gene in our AHDS patient. Both LT₄ and LT₃ administration had no therapeutic effect. Alternatively, treatment of AHDS patients with thyroid hormone analogs should be considered.

European Journal of Endocrinology 165 823–830

Introduction

Over the last 7 years, we have been investigating a child with severe psychomotor retardation and thyroid dysfunction, characterized initially by high triiodothyronine (T₃), borderline to low thyroxine (T₄), and normal TSH levels. The clinical phenotype and the thyroid hormonal pattern were suspected of the Allan–Herndon–Dudley syndrome (AHDS; OMIM #300523) (1). AHDS is known to be caused by mutations in the *SLC16A2* gene that encodes the monocarboxylate transporter 8 (MCT8) (2). This transporter is expressed in numerous human tissues including brain, heart, placenta, lung, kidney, skeletal muscle, and liver (3–5) and facilitates cellular T₃ uptake (6, 7). Subsequently, MCT8 mutations result in a diminished intracellular T₃ concentration (8, 9). Patients with *MCT8* gene mutations present with severe psychomotor retardation, generalized dystonia combined with spasticity, lack of verbal communication,

and poor head control and coordination (1, 8–17). These neurological characteristics were attributed to impaired MCT8 transporter activity into the neurons of the CNS (8, 18). All reported cases were males (except one female patient with unfavorable non-random X-activation (19)), since the *SLC16A2* gene is located on chromosome Xq13.2. Currently, no therapy is available for these patients, although a few interventions have been suggested to cope with some aspects of the syndrome (17, 20).

We describe here the genetic study and a follow-up of a child with AHDS who was treated with LT₄ for about 6.5 years and with low- and high-dose liothyronine (LT₃) for a short period of time. The treatment with high-dose LT₃ was intended to overcome the T₃ uptake inhibition at the CNS through alternative transport routes. Such routes could involve MCT10 and the organic anion transporting polypeptide 1A2 (OATP1A2), which facilitate T₃ uptake similar to MCT8 (3, 21).

Case study

The patient

The male patient was born by vaginal delivery to non-consanguineous parents, with a birth weight of 3950 g. At the age of 2 months, he was evaluated for poor head control, hypotonia of the shoulder girdle, and no visual tracking. An extensive genetic and metabolic work-up revealed normal karyotype, normal levels of urinary amino and organic acids, venous blood gases, and both serum and cerebrospinal fluid ammonia and lactate. Yet, liver enzymes were mildly elevated, with alanine aminotransferase (ALT) in the range of 35–38 U/l (normal levels 4–27 U/l) and aspartate aminotransferase (AST) in the range of 45–48 U/l (normal levels 8–29 U/l).

In addition, thyroid tests revealed an unusual pattern of elevated total T_3 up to 7.0 nmol/l (normal range 1.1–3.0 nmol/l), low to normal free T_4 (FT₄) levels (8.0–8.2 pmol/l, normal range 7.4–21.0 pmol/l), and normal TSH levels (2.9–4.3 mU/l). A standard thyrotropin-releasing hormone (TRH) stimulation test was performed at the age of 5 months. In response to IV administration of 100 $\mu\text{g}/\text{m}^2$ TRH, TSH increased from a basal level of 4.3 to a peak of 8.4 mU/l after 30 min, concomitantly with prolactin elevation from 348 to 583 mU/l. Since TSH elevation was below the expected values (22, 23), other pituitary hormones were examined, with normal response of GH to glucagon stimulation (peak level of 17 ng/ml) and cortisol to ACTH (synacthen) stimulation (peak level of 1397 nmol/l). At 7 years of age, a comprehensive evaluation of thyroid function of the index case and his family (father, mother, and two brothers) revealed high T_3 (4.06 nmol/l; normal range 1.4–2.5) and remarkably elevated T_3/rT_3 (reverse T_3) ratio (22.6; normal range 3.1–13.0) in the patient, with minute elevation of T_3 in one sibling (2.81 nmol/l) and normal tests in all other family members.

Brain magnetic resonance imaging (MRI) was performed at 6 months of age, revealing hypoplastic corpus callosum and delayed myelination of the brain. Auditory evoked response (at 8 months of age) and nerve conduction and needle electromyography (EMG) studies (at 7 years of age) were within the normal range. An abdominal ultrasound was performed at 10 months of age and revealed atrophic left kidney with normal right kidney and collecting system. This imaging was performed as part of a work-up for hypertension that was documented in the patient and spontaneously resolved after a short period of time. Renal function, expressed by serum creatinine levels, was normal over the years.

Between 6 months and 7 years of age, the patient was treated with LT₄ at daily doses that ranged from 25 to 64 μg (2.6–4.0 $\mu\text{g}/\text{kg}$ body weight). In response, TSH levels decreased from initial levels of 2.9–4.3 mU/l to

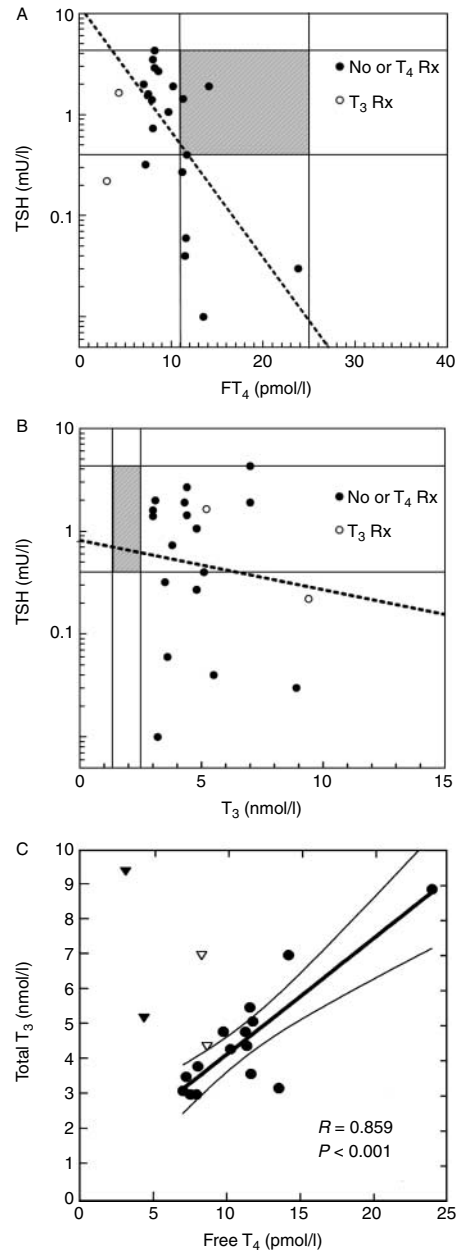


Figure 1 (A) Analysis of serum of the patient shows a negative correlation between TSH and free thyroxine (FT₄) levels (log TSH versus FT₄, $R = -0.52$, $P < 0.01$). The regression analysis included all TSH and FT₄ values that were measured before and after liothyronine (LT₃) administration (filled and open circles respectively). The shaded area represents the normal range of serum TSH and FT₄ concentrations. (B) Analysis of serum of the patient shows no correlation between TSH and total triiodothyronine (T₃) levels (log TSH versus T₃, $R = -0.14$, $P = \text{NS}$). The regression analysis included all TSH and T₃ values that were measured before and after LT₃ administration (filled and open circles respectively). The shaded area represents the normal range of serum TSH and T₃ concentrations. (C) Analysis of serum of the patient shows a positive correlation between FT₄ and T₃ levels during LT₄ treatment (filled circles; $R = 0.859$, $P < 0.001$). Thyroid hormone levels before treatment and during LT₃ therapy are depicted by open and filled triangles respectively.

levels in the range of 0.01–1.99 mU/l, maintaining a negative correlation with serum FT₄ ($R = -0.52$, $P < 0.01$; Fig. 1A) but not with T₃ levels ($R = -0.14$, NS; Fig. 1B). During LT₄ treatment, there was a positive correlation between serum FT₄ and T₃ levels ($R = 0.859$, $P < 0.001$; Fig. 1C). The T₃ levels before LT₄ treatment are well above this regression line with serum FT₄, suggesting that in untreated MCT8 patients, the elevated serum T₃ are derived at least in part from increased thyroidal T₃ secretion. Over those years, the patient was consistently growing along the 50th percentile in height and slightly below the 3rd percentile in weight.

Neurological examination at 7.5 years of age showed severe global developmental retardation, mainly in the motor and verbal aspects. The prominent signs were severe hypotonia mainly in the trunk with poor head control and no verticalization. The patient presented with increased muscle tone in the hamstring and gastrocnemius muscles and Achilles tendons, mild contracture of the knees, and augmented deep tendon reflexes without clonus. Fine motor skills were severely disturbed with inability to hold small objects to bring them to mouth or to pass them from side to side. The patient had involuntary, choreiform movements, repetitive dystonic smiles, and only rudimentary, non-verbal communication expressed by social smile and intentional look toward his family members and some medical persons.

After several years of LT₄ treatment at a final dose of 64 µg/day (4.0 µg/kg body weight), we initiated a washout period of 5 months, followed by LT₃ (cytomel) treatment in two doses of 12.5 µg twice daily and 25 µg twice daily, each dose administered over a period of 3 months. We initiated this LT₃ treatment in an attempt to improve some neurological functions of the patient.

The treatment was approved by the Ethics Committee of Kaplan Medical Center and we obtained written informed consent from both parents.

The clinical and endocrine data of this intervention are summarized in Table 1. Before LT₃ initiation, a heart rate of 114 was recorded with normal blood pressure. During treatment, the patient developed mild hypertension during both low- and high-dose LT₃ administration with only mild elevation in heart rate. There were no other signs compatible with hyperthyroidism, as body weight was increased during therapy, and no excessive sweating or hyperactivity was observed. Along with an increment in serum T₃ levels, FT₄, and TSH levels were progressively decreased, liver transaminases were mildly increased, and sex hormone-binding globulin (SHBG) was remarkably increased in response to the elevation in LT₃ doses. Yet, this intervention failed to induce any change in the patient's motor or cognitive functions. The cognitive skills of the patient were examined before and after LT₃ administration by a pediatric neurologist who found no change in verbal abilities and intentional facial expression.

Cytogenetic and SNP microarray studies

The DNA of the patient, his parents, and two brothers was extracted from peripheral lymphocytes by routine methods. PCR analysis of the MCT8 gene (*SLC16A2*) showed the presence of exon 1, while exons 2–6 were missing in the patient but not in his parents and brothers. Using this approach, it is not possible to discriminate between having one or two copies of the gene, meaning that we could not exclude that the mother was a heterozygous carrier of this X-chromosome deletion (Fig. 2A).

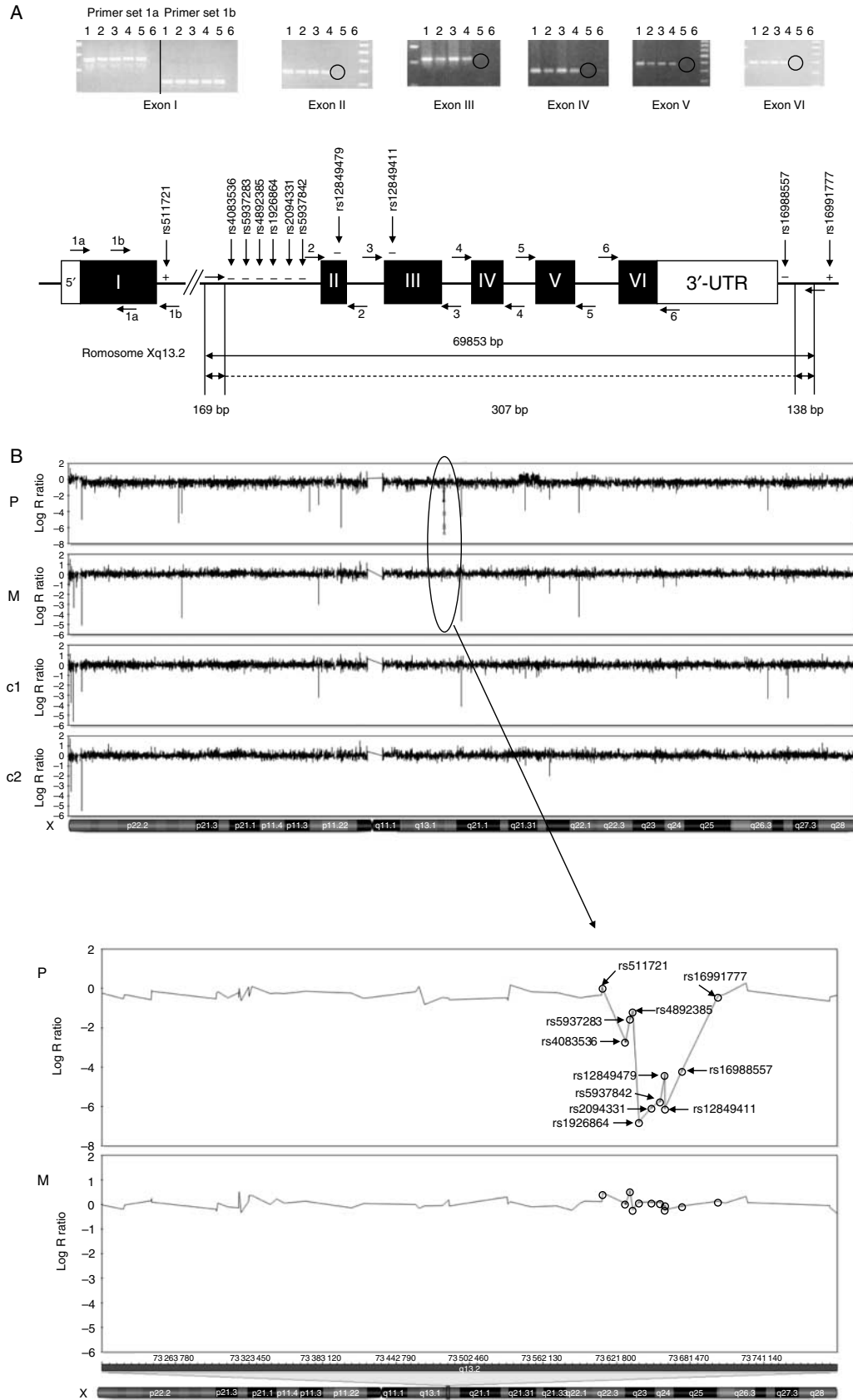
Table 1 Clinical parameters, thyroid hormones, and biochemical tests before and during low- and high-dose LT₃ administration. Normal ranges for age are in parenthesis. Values out of normal range are in bold.

	End of LT ₄	0 time (5 m off therapy)	+ 3 months	+ 6 months
Therapy (µg/day)	LT ₄ 64	LT ₃ 12.5 twice daily	LT ₃ 25 twice daily	End of therapy
Weight (kg)	16.4; -3.3 ^a	16.6; -3.3	17.0; -3.2	17.8; -2.9
Pulse (73–113)	100	114	115	120
Blood pressure (112/71) ^b	102/70	106/77	126/80	137/86
Free T ₄ (pmol/l; 11.0–22.0)	11.3	8.6	4.3	3.0
T ₃ (nmol/l; 0.9–2.8)	4.4	4.4	5.2	9.4
TSH (mU/l; 0.28–4.3)	1.43	2.68	1.64	0.22
SHBG (nmol/l; 13–71)	280	250	290	360
AST (U/l; 8–29)		33	29	49
ALT (U/l; 4–27)		32	29	67
LDH (U/l; 185–764)		443	398	502
GGT (U/l; 5–45)		12	12	20
Alk Phos (U/l; -410)		152	174	237
Creatinine (mg/dl; 0.2–0.7)		0.43	0.36	0.33
Cholesterol (mg/dl; 100–200)		193	165	181
Triglycerides (mg/dl; 40–166)		41	49	72

SHBG, sex hormone binding globulin; AST, aspartate aminotransferase; ALT, alanine aminotransferase; Alk Phos, Alkaline Phosphatase; LDH, lactate dehydrogenase; GGT, gamma-glutamyl transpeptidase.

^aWeight in Z-score.

^b90th percentile for age.



In order to define the approximate size of the deletion, to see whether other genes were located within the deletion, and to determine whether the mother was a carrier, we used the Illumina Infinium II HumanHap 610K SNP Genotyping BeadChip (Illumina, Inc., San Diego, CA, USA). Genotyping procedures were followed according to Illumina manufacturer's protocols. Using the genomic DNA of the patient and his mother together with two randomly selected female controls, we determined that the deletion was only present in the DNA of the patient and therefore concluded that the deletion was likely of a *de novo* origin since the mother was not a carrier. We observed the complete loss of nine SNPs between rs511721 and rs16991777 spanning maximal 113.7 kb (Fig. 2B). Finally, the exact borders of the deleted segment were defined by PCR-based fine mapping, yielding a deletion spanning 69 546 bp on chromosome Xq13.2 and comprising five of six exons of *SLC16A2* (Fig. 2B) confirming that the deletion in this patient was limited to the *SLC16A2* gene.

Discussion

We had the chance to follow a patient with AHDS and to evaluate the clinical and endocrine response to a long-term treatment with LT_4 and to a 6-month period of LT_3 therapy. His severe global development retardation derives from an almost complete deletion (five of six exons) of the *SLC16A2* gene and thus likely involves complete inactivation of MCT8 function. Unlike our patient, several reported AHDS patients with mutations in the *SLC16A2* gene showed residual activity of the MCT8 (1, 8) and some of them developed walking and speech capacity (1). It has been suggested that these patients with partial inactivation of MCT8 might benefit from thyroid hormone treatment (7).

Although our patient was not an ideal candidate for such intervention at his relatively advanced age and conceivably complete inactivation of the MCT8, we hypothesized that the complete cellular resistance to T_3 uptake can be partially overcome through alternative T_3 transporters, e.g. MCT10 and OATP1A2 (*SLCO1A2*). MCT10 is a thyroid hormone transporter that preferentially facilitates cellular T_3 uptake more effectively than MCT8. *MCT10* (*SLC16A10*) mRNA is expressed in various tissues, with relatively low levels of expression in the brain (21), although recent studies performed by Alkemade *et al.* (24) showed high expression of MCT10 in specific areas of the human hypothalamus. OATP1A2 facilitates the transmembrane transport of thyroid

hormones including T_3 and is expressed in multiple tissues including the brain. Although it has a low specificity for thyroid hormones and probably plays a minor role as a thyroid hormone transporter, it has been suggested that it may serve as a back-up system in case of other transporters malfunction (3). LT_3 treatment was examined only once in an AHDS patient with a complete loss of function of the MCT8 transporter, yielding no clinical improvement (17). In spite of these discouraging results, we aimed to examine the effect of higher doses of LT_3 for a longer period of time, since LT_3 in the previous study was administered only for about a month and later for a week, periods that might be too short to conclusively dismiss possible effects of LT_3 treatment, especially in the CNS. Similar to the gradual response of peripheral organs to increasing levels of serum T_3 (17), we assumed that the CNS might respond to T_3 concentrations that exceed a certain threshold. Notably, we have started LT_3 administration at serum T_3 levels that were significantly lower than levels recorded during infancy (4.4 vs 7.0 nmol/l respectively).

During administration of high-dose LT_3 , we observed a significant elevation of T_3 levels that exceeded the highest levels recorded during infancy, but no improvement of motor or cognitive skills could be detected by the pediatric neurologist. There are several possible explanations for the unresponsiveness to the treatment. First, the harmful effect of neuronal T_3 deprivation *in utero*, a critical period for brain development, may be irreversible and permanent after birth. While athyreotic infants or those with an inability to synthesize T_4 maintain essential levels of thyroid hormones *in utero* by trans-placental transfer from the mother (25), those with MCT8 inactivation cannot compensate for T_3 absence in the neurons, even by remarkably elevated T_3 levels. This may also explain the remarkable severity of AHDS patients compared with the old reports of patients with untreated congenital hypothyroid, especially in motor skills (26).

The devastating irreversible effect of thyroid hormone transport resistance can also be reflected by the brain structural damage associated with MCT8 dysfunction. Our patient displayed hypoplastic corpus callosum and delayed myelination of the brain in MRI performed at 6 months of age. Similarly, others have shown subtle cortical and subcortical atrophy (17) or delayed myelination from infancy (15, 27). The thyroid hormone treatment failure may alternatively be attributed to the introduction of the hormones late in life, i.e. well beyond a window of opportunity that may theoretically exist during the first weeks of life. Finally,

Figure 2 (A) PCR analysis of the six exons of *SLC16A2* in the patient, his parents, and two brothers. The analysis generated amplicons of all six exons in the family members but no amplification of exons 2–6 in the patient (circles). 1, mother; 2, father; 3, brother 1; 4, brother 2; 5, patient; 6, negative control. (B) The exact borders of the deleted segment defined by using the Illumina Infinium II HumanHap 610K SNP array data and PCR-based fine mapping. Results from the X-chromosome of the patient (P) and his mother (M) together with two randomly selected female controls (c1 and c2) revealing the complete loss of nine SNPs only in the DNA of the patient. The deletion is limited to the *SLC16A2* region defined between rs511721 and rs16991777, ultimately yielding a deletion of 69 546 bp. Scheme is not on scale.

it is possible that the alternative transporters, namely MCT10 and OATP1A2, cannot adequately compensate for the MCT8 dysfunction and its associated severe neurological consequence.

A different approach was suggested by Wemeau *et al.* (20), who demonstrated a significant weight gain in a malnourished adolescent with AHDS, in response to a combined administration of propylthiouracil and LT_4 . Yet, this treatment had no beneficial effect on the neurological condition of the adolescent patient.

Several years of LT_4 treatment and a short exposure of our patient to LT_3 shed some light on the effects of thyroid hormone at the hypothalamus/pituitary level as well as the peripheral organs such as heart and liver. The pituitary gland was resistant to the suppressing effect of initial high T_3 levels on TSH secretion, as TSH levels were within the normal range in spite of T_3 levels up to 7.0 nmol/l. This resistance to T_3 was observed over the years, demonstrated by a lack of TSH suppression in response to elevated T_3 serum levels (Fig. 1B). Nevertheless, it was only a partial resistance since TSH levels (and subsequently FT_4 levels) were remarkably suppressed in response to the gradual elevation in T_3 levels during low- and especially high-dose LT_3 treatment (Table 1). Furthermore, basal T_3 imposed some suppressing effect on TSH elevation during TRH stimulation test, an observation that was reported by others (17, 28). In the human pituitary gland, MCT8 is expressed in the folliculostellate cells rather than the TSH-producing cells (29). It is assumed that these sites are involved in the negative feedback control of TRH in the hypothalamus and TSH in the pituitary gland by thyroid hormones (7). In our patient, who conceivably had complete inactivation of the MCT8 protein due to the deletion of an extended segment of the *SLC16A2* gene, it is possible that the observed T_3 effects were mediated by alternative T_3 transporters (e.g. MCT10 and OATP1A2) located in the pituitary gland and the hypothalamus.

Unlike partial resistance to T_3 , the patient was sensitive to even mild elevation in FT_4 levels during LT_4 administration, presented as a reverse correlation between FT_4 and TSH serum levels (Fig. 1A). LT_4 treatment was previously reported in three other AHDS patients with a single-nucleotide substitution or deletion (15–17), compared to an almost complete deletion of the *MCT8* gene in our patient. Yet, in spite of the distinct genetic differences, all four patients presented with a similar suppression of TSH and no change in cardiovascular indices or neurological functions in response to LT_4 administration. Based on these limited data, it is conceivable that the response to LT_4 is unrelated to the type of the genetic defect. Similarly, we could not detect an association between thyroid hormones and TSH levels at baseline and the type of mutation or size of deletion. Hence, while our patient presented with very high T_3 and normal TSH levels, another patient with a large deletion in *MCT8*

gene of about 25 000 bp (8) presented with high levels of both TSH (8.8 mU/l) and T_3 (6.1 nmol/l). Notably, high levels of T_3 (7.3 nmol/l) were documented in a patient with a missense mutation (10) whereas normal levels of TSH were reported in many patients with all kinds of small size mutations and deletions (7, 8, 17, 20).

At the periphery, the cardiovascular system was responding to high T_3 levels by mild tachycardia and hypertension (both chronotropic and inotropic effects) and the liver responded by SHBG elevation (and mild elevation in transaminase enzymes) in parallel with LT_3 dose and T_3 levels. Our patient had unilateral atrophic kidney. Although MCT8 is expressed in the kidney of rats (2) and mice (30), structural defects of the kidney were not reported in AHDS; hence, this finding in our patient is probably incidental. Unlike the reported increased sweating (17) and impaired weight gain that was attributed to a deleterious effect of high T_3 at the adipose tissue (17, 20), our patient did not display these signs of clinical hyperthyroidism but rather gained weight during LT_3 administration. We suggest that the low weight gain, common in AHDS (1), is derived from feeding problems in severely retarded patients rather than from high T_3 -related hypermetabolic state. Indeed, Wemeau *et al.* (20) found no significant change in resting energy expenditure measured in their AHDS patient, in spite of T_3 suppression to normal levels during propylthiouracil (PTU) treatment. Alternatively, different responses of peripheral organs to elevated serum levels of T_3 , due to variability in the residual function of MCT8 transporter, may account for differences in hyperthyroid symptoms, including weight gain and loss among these patients. It should be emphasized that although weight loss in hyperthyroidism is common despite an increase in appetite, the occasional patient gains weight if caloric intake exceeds the metabolic rate (31). The mother of our patient has reported some better compliance for feeding during the LT_3 course but no significant change in food intake.

In conclusion, even in a severe case with extended deletion of the *MCT8* gene and apparently complete inactivation of the protein, some central responsiveness to T_3 was observed along with peripheral responsiveness at the heart and the liver. These observations may reflect variability in MCT8 expression at different tissues or a role of alternative T_3 transport systems. Unfortunately, these transporters could not mediate any motor or cognitive improvement in our patient, even in response to high doses of LT_3 . An early administration of thyroid hormones during infancy, especially in AHDS patients with partial activity of the MCT8, should be examined (7). Another therapeutic option in the future might be the administration of a thyroid hormone analog with reduced dependence on the MCT8 for cellular uptake that showed promising results in *MCT8* knockout mice (32).

Declaration of interest

The authors declare that there is no conflict of interest that could be perceived as prejudicing the impartiality of the research reported.

Funding

This research did not receive any specific grant from any funding agency in the public, commercial or not-for-profit sector.

Acknowledgements

We thank Hans van Toor and Mila Jhamai for excellent technical assistance.

References

- Schwartz CE, May MM, Carpenter NJ, Rogers RC, Martin J, Bialer MG, Ward J, Sanabria J, Marsa S, Lewis JA, Echeverri R, Lubs HA, Voeller K, Simensen RJ & Stevenson RE. Allan–Herndon–Dudley syndrome and the monocarboxylate transporter 8 (MCT8) gene. *American Journal of Human Genetics* 2005 **77** 41–53. (doi:10.1086/431313)
- Friesema EC, Ganguly S, Abdalla A, Manning Fox JE, Halestrap AP & Visser TJ. Identification of monocarboxylate transporter 8 as a specific thyroid transporter. *Journal of Biological Chemistry* 2003 **278** 40128–40135. (doi:10.1074/jbc.M300909200)
- van der Deure WM, Peeters RP & Visser TJ. Molecular aspects of thyroid hormone transporters, including MCT8, MCT10 and OATPs, and the effects of genetic variation in these transporters. *Journal of Molecular Endocrinology* 2010 **44** 1–11. (doi:10.1677/JME-09-0042)
- Price NT, Jackson VN & Halestrap AP. Cloning and sequencing of four new mammalian monocarboxylate transporter (MCT) homologues confirms the existence of a transporter family with an ancient past. *Biochemistry Journal* 1998 **329** 321–328.
- Chan SY, Franklyn JA, Pemberton HN, Bulmer JN, Visser TJ, McCabe CJ & Kilby MD. Monocarboxylate transporter 8 expression in the human placenta: the effects of severe intrauterine growth restriction. *Journal of Endocrinology* 2006 **189** 465–471. (doi:10.1677/joe.1.06582)
- Friesema EC, Kuiper GG, Jansen J, Visser TJ & Kester MH. Thyroid hormone transport by the human monocarboxylate transporter 8 and its rate-limiting role in intracellular metabolism. *Molecular Endocrinology* 2006 **20** 2761–2772. (doi:10.1210/me.2005-0256)
- Visser WE, Friesema EC, Jansen J & Visser TJ. Thyroid hormone transport in and out of cells. *Trends in Endocrinology and Metabolism* 2007 **19** 50–56. (doi:10.1016/j.tem.2007.11.003)
- Jansen J, Friesema CH, Kester MHA, Milici C, Reeser M, Gruters A, Barrett TG, Mancilla EE, Svensson J, Wemeau JL, Canalli MH, Lundgren J, McEntagart ME, Hopper N, Arts WF & Visser TJ. Functional analysis of monocarboxylate transporter 8 mutations identified in patients with X-linked psychomotor retardation and elevated serum triiodothyronine. *Journal of Clinical Endocrinology and Metabolism* 2007 **92** 2378–2381. (doi:10.1210/jc.2006-2570)
- Maranduba CM, Friesema EC, Kok F, Kester MH, Jansen J, Sertie AL, Passos-Bueno MR & Visser TJ. Decreased cellular uptake and metabolism in Allan–Herndon–Dudley syndrome (AHDS) due to a novel mutation in the MCT8 thyroid hormone transporter. *Journal of Medical Genetics* 2006 **43** 457–460. (doi:10.1136/jmg.2005.035840)
- Friesema EC, Gruters A, Biebermann H, Krude H, von Moers A, Reeser M, Barrett TG, Mancilla EE, Svensson J, Kester MHA, Kuiper GGJ, Balkassmi S, Uitterlinden AG, Koehle J, Rodien P, Halestrap AP & Visser TJ. Association between mutations in a thyroid hormone transporter and severe X-linked psychomotor retardation. *Lancet* 2004 **364** 1435–1437. (doi:10.1016/S0140-6736(04)17226-7)
- Dumitrescu AM, Liao XH, Best TB, Brockmann K & Refetoff S. A novel syndrome combining thyroid and neurological abnormalities is associated with mutations in a monocarboxylate transporter gene. *American Journal of Human Genetics* 2004 **74** 168–175. (doi:10.1086/380999)
- Kakinuma H, Iton M & Takahashi H. A novel mutation in the monocarboxylate transporter 8 gene in a boy with putamen lesions and low free T₄ levels in cerebrospinal fluid. *Journal of Pediatrics* 2005 **147** 552–554. (doi:10.1016/j.jpeds.2005.05.012)
- Holden KR, Zuniga OF, May MM, Su H, Molinero MR, Rogers RC & Schwartz CE. X-linked MCT8 gene mutation: characterization of the pediatric neurologic phenotype. *Journal of Child Neurology* 2005 **20** 852–857. (doi:10.1177/08830738050200101601)
- Herzovich V, Vaiani E, Marino R, Dratler G, Lazzati JM, Tilitzky S, Ramirez P, Iorcansky S, Rivarola MA & Belgorosky A. Unexpected peripheral markers of thyroid function in a patient with a novel mutation of the MCT8 thyroid hormone transporter gene. *Hormone Research* 2007 **67** 1–6. (doi:10.1159/000095805)
- Namba N, Etani Y, Kitaoka T, Nakamoto Y, Nakacho M, Bessho K, Niyoshi Y, Mushiaki S, Mohri I, Arai H, Taniike M & Ozono K. Clinical phenotype and endocrinological investigations in a patient with a mutation in the MCT8 thyroid hormone transporter. *European Journal of Pediatrics* 2008 **167** 785–791. (doi:10.1007/s00431-007-0589-6)
- Papadimitriou A, Dumitrescu AM, Papavasiliou A, Fretzayas A, Nicolaidou P & Refetoff S. A novel monocarboxylate transporter 8 gene mutation as a cause of severe neonatal hypotonia and developmental delay. *Pediatrics* 2008 **121** e199–e202. (doi:10.1542/peds.2007-1247)
- Biebermann H, Ambrugger P, Tarnow P, von Moers A, Schweizer U & Grueters A. Extended clinical phenotype, endocrine investigations and functional studies of a loss-of-function mutation A150V in the thyroid hormone specific transporter MCT8. *European Journal of Endocrinology* 2005 **153** 359–366. (doi:10.1530/eje.1.01980)
- Heuer H, Maier MK, Iden S, Mittag J, Friesema EC, Visser TJ & Bauer K. The monocarboxylate transporter 8 linked to human psychomotor retardation is highly expressed in thyroid hormone-sensitive neuron populations. *Endocrinology* 2005 **146** 1698–1700. (doi:10.1210/en.2004-1179)
- Frints SG, Lenzner S, Bauters M, Jensen LR, van Esch H, des Portes V, Moog U, Macville MV, van Roozendaal K, Schrandt-Stumpel CT, Tzschach A, Marynen P, Fryns JP, Hamel B, van Bokhoven H, Chelly J, Beldjord C, Turner G, Gez J, Moraine C, Raynaud M, Ropers HH, Froyen G & Kuss AW. MCT8 mutation analysis and identification of the first female with Allan–Herndon–Dudley syndrome due to loss of MCT8 expression. *European Journal of Human Genetics* 2008 **16** 1029–1037. (doi:10.1038/ejhg.2008.66)
- Wemeau JL, Pigeire M, Proust-Lemoine E, d'Herbomez M, Gottard F, Jansen J, Visser TJ & Ladsous M. Beneficial effects of propylthiouracil plus l-thyroxine treatment in a patient with a mutation in MCT8. *Journal of Clinical Endocrinology and Metabolism* 2008 **93** 2084–2088. (doi:10.1210/jc.2007-2719)
- Friesema EC, Jansen J, Jachtenberg JW, Visser WE, Kester MHA & Visser TJ. Effective cellular uptake and efflux of thyroid hormone by human monocarboxylate transporter 10. *Molecular Endocrinology* 2008 **22** 1357–1369. (doi:10.1210/me.2007-0112)
- Okuno A, Taguchi T, Nakayama K & Takimoto M. Kinetic analysis of plasma TSH after TRH stimulation. *Hormone Research* 1979 **11** 293–295. (doi:10.1055/s-0028-1092726)
- Rapaport R, Sills I, Patel U, Oppenheimer E, Skuza K, Horlick M, Goldstein S, Dimartino J & Saenger P. Thyrotropin-releasing hormone stimulation tests in infants. *Journal of Clinical Endocrinology and Metabolism* 1993 **77** 889–894. (doi:10.1210/jc.77.4.889)

- 24 Alkemade A, Friesema EC, Kalsbeek A, Swaab DF, Visser TJ & Fliers E. Expression of thyroid hormone transporters in the human hypothalamus. *Journal of Clinical Endocrinology and Metabolism* 2011 **96** E967–E971. (doi:10.1210/jc.2010-2750)
- 25 Vulsma T, Gons MH & de Vijlder JJ. Maternal–fetal transfer of thyroxine in congenital hypothyroidism due to a total organification defect or thyroid agenesis. *New England Journal of Medicine* 1989 **321** 13–16. (doi:10.1056/NEJM198907063210103)
- 26 Larsen PR, Davies TF & Hay ID. The thyroid gland. In *Williams Textbook of Endocrinology*, 9th edn, pp 460–475. Eds JD Wilson, DW Foster, HM Kronenberg & PR Larsen. Philadelphia: W.B. Saunders Company, 1998.
- 27 Vaurs-Barriere C, Deville M, Sarret C, Giraud G, Des Portes V, Prats-Vinas JM, De Michele G, Dan B, Brady AF, Boespflug-Tanguy O & Touraine R. Pelizaeus–Merzbacher-like disease presentation of MCT8 mutated male subjects. *Annals of Neurology* 2009 **65** 114–118. (doi:10.1002/ana.21579)
- 28 Boccone L, Mariotti S, Dessi V, Pruna D, Meloni A & Loudianos G. Allan–Herndon–Dudley syndrome (AHDS) caused by a novel *SLC16A2* gene mutation showing severe neurologic features and unexpectedly low TRH-stimulated serum TSH. *European Journal of Medical Genetics* 2010 **53** 392–395. (doi:10.1016/j.ejmg.2010.08.001)
- 29 Alkemade A, Friesema EC, Kuiper GG, Wiersinga WM, Swaab DF, Visser TJ & Fliers E. Novel neuroanatomical pathways for thyroid hormone action in the human anterior pituitary. *European Journal of Endocrinology* 2006 **154** 491–500. (doi:10.1530/eje.1.02111)
- 30 Becker HM, Mohebbi N, Perna A, Ganapathy V, Capasso G & Wagner CA. Localization of members of MCT monocarboxylate transporter family Slc16 in the kidney and regulation during metabolic acidosis. *American Journal of Physiology. Renal Physiology* 2010 **299** F141–F154. (doi:10.1152/ajprenal.00488.2009)
- 31 Larsen PR, Davies TF & Hay ID. The thyroid gland. In *Williams Textbook of Endocrinology*, 9th edn, ch 11, pp 389–516. Eds JD Wilson, DW Foster, HM Kronenberg & PR Larsen. Philadelphia: W.B. Saunders Company, 1998.
- 32 Di Cosmo C, Liao XH, Dumitrescu AM, Weiss RE & Refetoff S. A thyroid hormone analog with reduced dependence on the monocarboxylate transporter 8 for tissue transport. *Endocrinology* 2009 **150** 4450–4458. (doi:10.1210/en.2009-0209)

Received 22 April 2011

Revised version received 17 August 2011

Accepted 5 September 2011